


PATIENT

A169298 BAS

SPECIES

Feline

BREED

DSH

SEX

Male Neutered

AGE

~ 5years

WEIGHT

11.5lbs

INTERPRETED BY

 Maggie Machen Lamy,
 DVM DACVIM
 (Cardiology)

IMAGING PERFORMED BY

Kelly Reschny, RVT

HOSPITAL NAME

 Snelgrove Veterinary
 Service

REFERRING VET

Dr. Gunsinger

INVOICE

24680

DATE

6/9/22

PRESENTING CLINICAL SIGNS

History: Shelter cat. Surrender, no known history. Significant arrhythmia present on auscultation with grade II-III/VI systolic murmur noted. Neutered with no complications, arrhythmia persisted under anesthetic. Medications: Gabapentin 100mg PO prior to U/S

ELECTROCARDIOGRAPHIC FINDINGS *Note: Single lead ECGs are evaluated as a rhythm strip. Morphology/MEA cannot be definitively commented on.

A single lead ECG is available; 50mm/s, 20mm/mV. The average heart rate is 160bpm (range 150-176bpm). The rhythm is sinus in origin, with a p for every QRS complex and vice versa. The P and QRS morphologies are positive. No ectopic beats, pauses or other dysrhythmias observed.

ECG diagnosis: Normal sinus tachycardia.

ECHOCARDIOGRAM FINDINGS

2D, m-mode, color flow and doppler imaging is available. The left ventricular wall is normal in dimension. There is a diffusely hyperechoic endocardium consistent with fibrosis. The papillary muscles are mildly remodeled and hyperechoic. The endocardium also appears remodeled. The left atrium is normal in size. The right atrium is normal in size. The right ventricle appears normal. The mitral valve is normal in structure and mobility. Blood flow through both the LVOT and RVOT is normal in velocity. No pleural or pericardial effusion seen. No obvious cardiac tumors.

CARDIAC CHART

FELINE CARDIAC PARAMETERS	BODY WEIGHT (kg)	HR (BPM)	IVSd (cm) (Moise, Pipers)	LVIDd (cm) (Moise, Pipers)	LVWd (cm) (Moise, Pipers)	FS (%)	EF (%)
NORMAL PARAMETER	-----	150-240	0.35-0.55	<2 (mean 1.5)	3.5-0.55	35-67	80-100
PATIENT	5.2	200	0.44	1.57	0.44	70	96
FELINE CARDIAC PARAMETERS	LA/AO (Boon)	LA/AO HEART BASE (Swe) (Abbott)	LA 2D short axis Base view (cm) (Abbott)	LVOT VEL (m/s)	RVOT VEL (m/s)	E max (m/s)	
NORMAL	<1.5	<1.3	<1.2	<1.6	<1.3	<0.9	
PATIENT	1.3	1.1	1.0	1.0	0.85	NM	
*Note: All measurements based upon multi-modal images and methods. An average value is reported. Adapted from June Boon, Veterinary Echocardiography, 1998 Abbott J & MacLean H JVIM 2006;20: 111-119, Moise et al. Am J Vet Res 47:1476, 1986. Pipers et al. Am J Vet Res 40:882, 1979.							

INTERPRETATION OF THE FINDINGS & FURTHER RECOMMENDATIONS

Overtly normal cardiac structure and function. The LV wall thickness is normal and there is no evidence of elevated left atrial pressure. There is mild remodeling and fibrosis of the left ventricular wall, which is likely a normal variant. Serial echocardiography will be necessary to determine progression. Additionally, no cause for the murmur is identified in this study, making it likely physiologic in origin (i.e., secondary to tachycardia, volume changes, etc.).



PATIENT

A169298 BAS

The submitted ECG is normal, with no evidence of dysrhythmias. If these findings do not reflect what was ausculted on exam (ie premature beats), a longer recording or potentially a holter monitor may be necessary.

SPECIES

Feline

Given these findings, no medications are indicated.

BREED

DSH

No cardiac contraindication for general anesthesia. Mild IV fluid restriction is advised. Risk for complication with steroid use typically follows LA dilation, which in this case is low. That being said, any cat can experience unexpected signs of intolerance and monitoring of RR/RE is advised particularly in the initiation phase.

SEX

Male Neutered

Recommend recheck echocardiogram in 1 year to reassess murmur origin, and screen for development of disease the pre-existing murmur may mask.

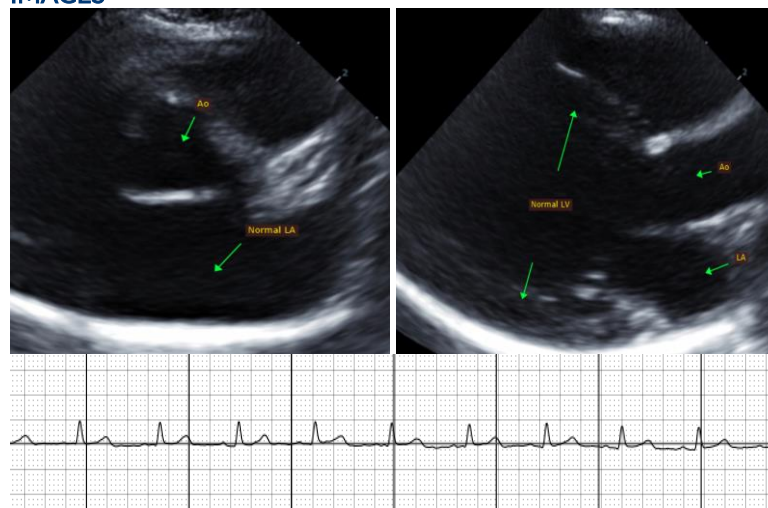
IMAGES

AGE

~ 5years

WEIGHT

11.5lbs



INTERPRETED BY

Maggie Machen Lamy,
DVM DACVIM
(Cardiology)

IMAGING PERFORMED BY

Kelly Reschny, RVT

The information and recommendations provided are based on the images presented by the referring veterinarian. No evaluation can be communicated regarding pathology that was not visible in the image/video clips provided.

HOSPITAL NAME

Snelgrove Veterinary
Service

Thank you for this referral. This report was generated using transcription software, and minor dictation errors may be present. If the clinical or image interpretation does not parallel your findings or if I can be of any further assistance, please contact me.

REFERRING VET

Dr. Gunsinger

Maggie Machen Lamy, DVM
Diplomate of the American College of Veterinary Internal Medicine (Cardiology)
info@sonopath.com

INVOICE

24680

DATE

6/9/22